

When suitable hard and soft tissues conditions are present, immediate implant placement using two-part implants with their various abutment options and their prosthetic flexibility that allows for the preservation of the emergence profile of the original tooth, is an established modality in implantology. Clinical data and case presentations on immediate placement and immediate restoration of reversible screwed two-piece ceramic implant are not yet available. For the reader, we share our experience with two case presentations showing the clinical possibilities and limitations.

# Immediate Implant Placement in the Aesthetic zone

## Possibilities and limitations of ceramic implants.

Prof. Dr. med. Dr. med. dent. Michael Stiller, Dr. Barbara Peleska

The available clinical studies of immediate implant placement show success rates between 96.9 and 100% after four or five years, but this promising data has only been gathered with titanium implants. 1,2 These numbers were obtained from a 2015 review of published articles and case studies involving 1,170 patients. 3 It is therefore proven in the scientific literature that immediate implant placement with a wide range of provisional restorations is an integral part of the therapeutic spectrum for anterior

edentulous situations. Although the data shows there is no difference in the implant stability quotient (ISQ) of dental implants between patient groups with implants that healed under function and those with implants placed without loading, it is to be assumed that the rate of loss increases when there is immediate placement with insufficient primary stability and functional load during the healing phase.4

Implementation of an immediate placement requires

sufficient buccal bone volume, a stable periodontal status, a stable soft tissue phenotype as well as pre-planning of orofacial aesthetics, which, in the case of an extraction and insertion of an implant, does not permit clinically and aesthetically relevant changes of the anterior appearance.5 A pre-requisite for such an approach is the ability to achieve sufficient primary stability – under conditions in which the implant has a lower contact area to the local bone compared to a delayed implantation, thus effectively providing a lower osseointegrative potential. In most cases, in order to achieve a sustainable survival of the implant under occlusal load, a two-piece implant system is preferred if the three-dimensional mucogingival requirements of an immediate placement

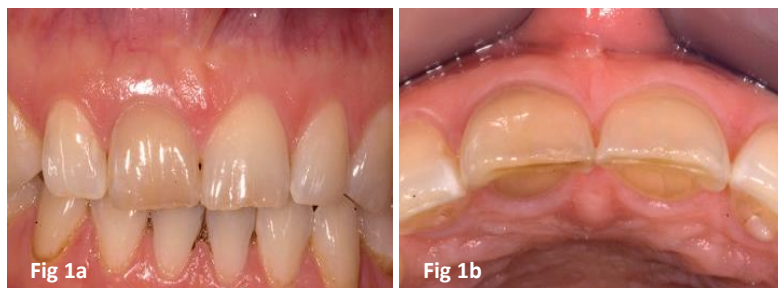
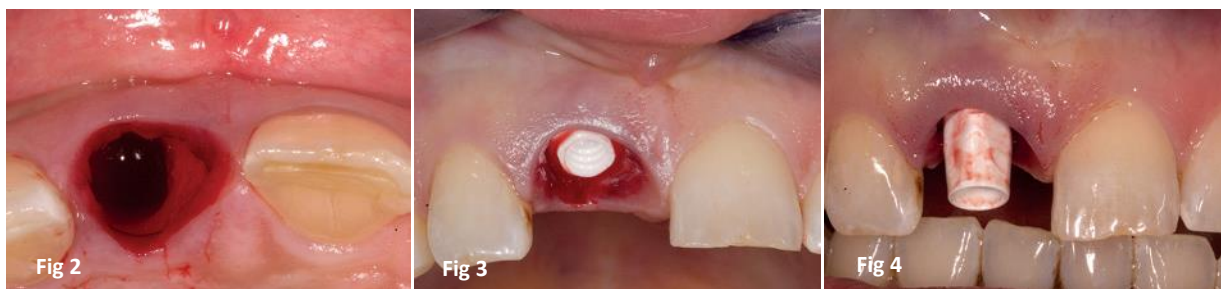
Fig 1a and 1b: Original situation – buccal and incisal views



**Fig 2:** The fractured tooth could be removed atraumatically without bone loss after removal of the provisional crown. **Fig 3:** After the osteotomy the implant was positioned slightly palatally with primary stability. **Fig 4:** Screwed zirconia abutment.

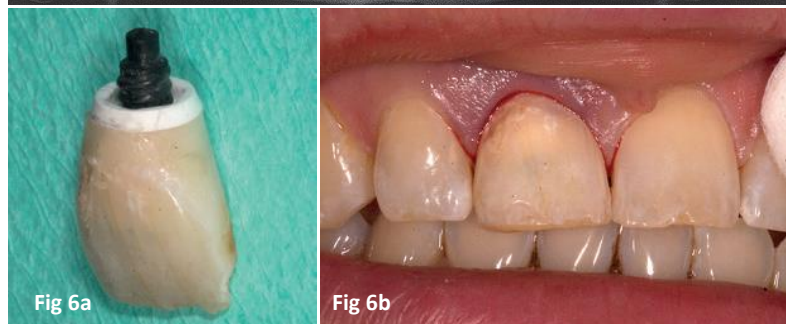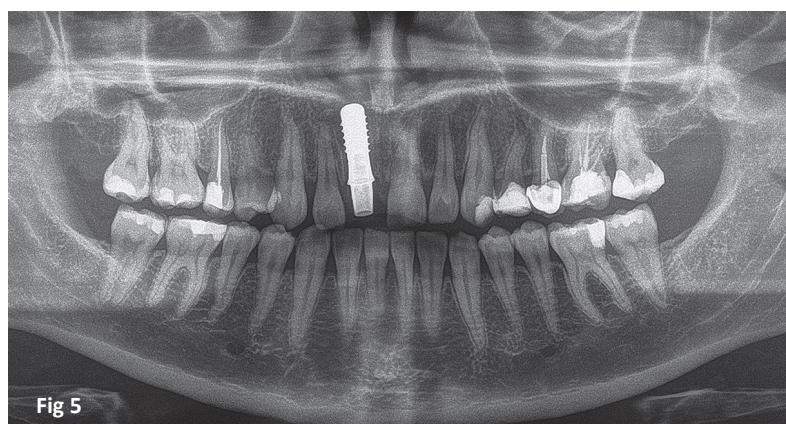
are met and an immediate temporary restoration is possible. This was, until a few years ago, only possible with titanium implants using conventional prefabricated abutment systems or CAD/CAM milled titanium and/or zirconium dioxide abutments.

With the technical development of reversible metallic and non-metallic screwed connections between implant and abutment in the last few years, ceramic implants are now indicated in the aesthetic zone. Therefore, these systems are increasingly becoming a real alternative to titanium and one-piece ceramic implants.<sup>6</sup> Relevant clinical studies of two-piece ceramic implant systems are currently only available for non-reversible connection (adhesive bonding). These already show promising results in terms of red and white aesthetics while modern ceramic implant systems are proven to have an acceptable rate of bone resorption comparable to titanium systems.<sup>7-10</sup> It is now possible, due to the above-mentioned technical innovations, to implement the use of all-ceramic implants in

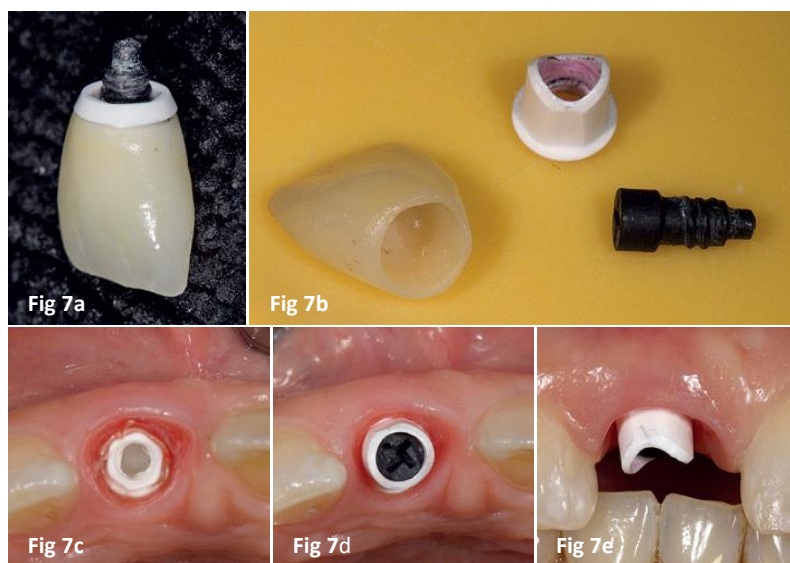
the context of immediate implant placement and immediate restoration. More importantly, the benefits of ceramic implants with regards to their excellent biocompatibility, low plaque affinity, high primary stability, excellent soft tissue response and aesthetic performance even in case of thin soft tissue phenotype, can be used for best results.

Treatment Case 1

A 25-year-old patient presented with a transverse fracture in tooth # 11. The tooth had been endodontically treated 15 year earlier after having undergone a trauma and a provisional plastic crown was placed a month before the procedure. The patient had a thick, stable soft tissue phenotype with enough apical bone volume and a wide inter-proximal bone septum. The patient had a



**Fig 5:** OPG control image. **Fig 6a and 6b:** The temporary crown was made with a light-curing composite bonded to the straight zirconia abutment.



**Fig 7a to 7e:** After dental optimization with recontouring and polishing, the one-piece crown abutment complex is screwed to the implant via a carbon fibre screw with a torque of 25 Ncm2.

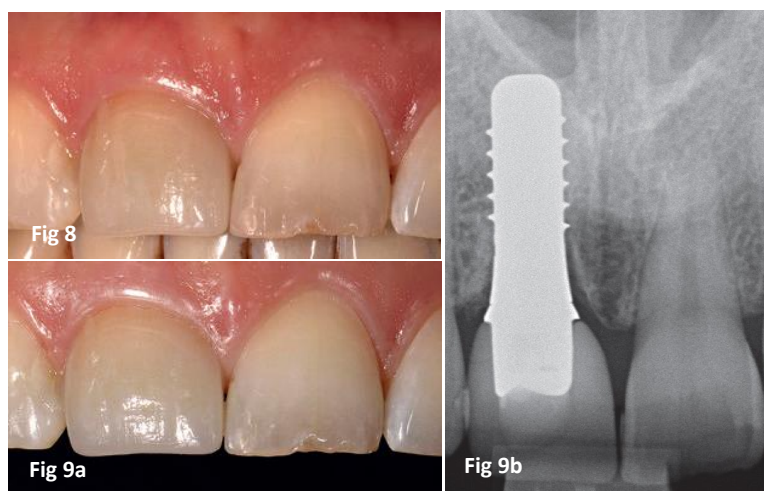
malocclusion but declined either orthodontic treatment or complex occlusal rehabilitation. She explicitly wished to receive ceramic implant prosthetic care.

Because of the excellent hard and soft tissue morphology in the prospective site # 11, an immediate implant placement with immediate restoration was planned. To this end a silicone key of the maxillary anterior region was prepared before the procedure. After the removal of the provisional crown, the atraumatic removal of the fractured tooth was performed without bone loss. As planned a three-dimensional analysis of the hard and soft tissues was performed before the immediate implant placement. The buccal cortical plate was undamaged during the exodontia. The implant system (ZERAMEX® P6, Dentalpoint AG) has a user-friendly surgical protocol and the osteotomy was

performed slightly palatally and positioned palatal to the incisal edge of the original tooth with good primary stability, as indicated. The buccal space thus created within the alveola was filled with bone fragments collected during the osteotomy. The intact provisional crown was set in the silicone key and then positioned over a straight screwed zirconia abutment using light-cured composite. After

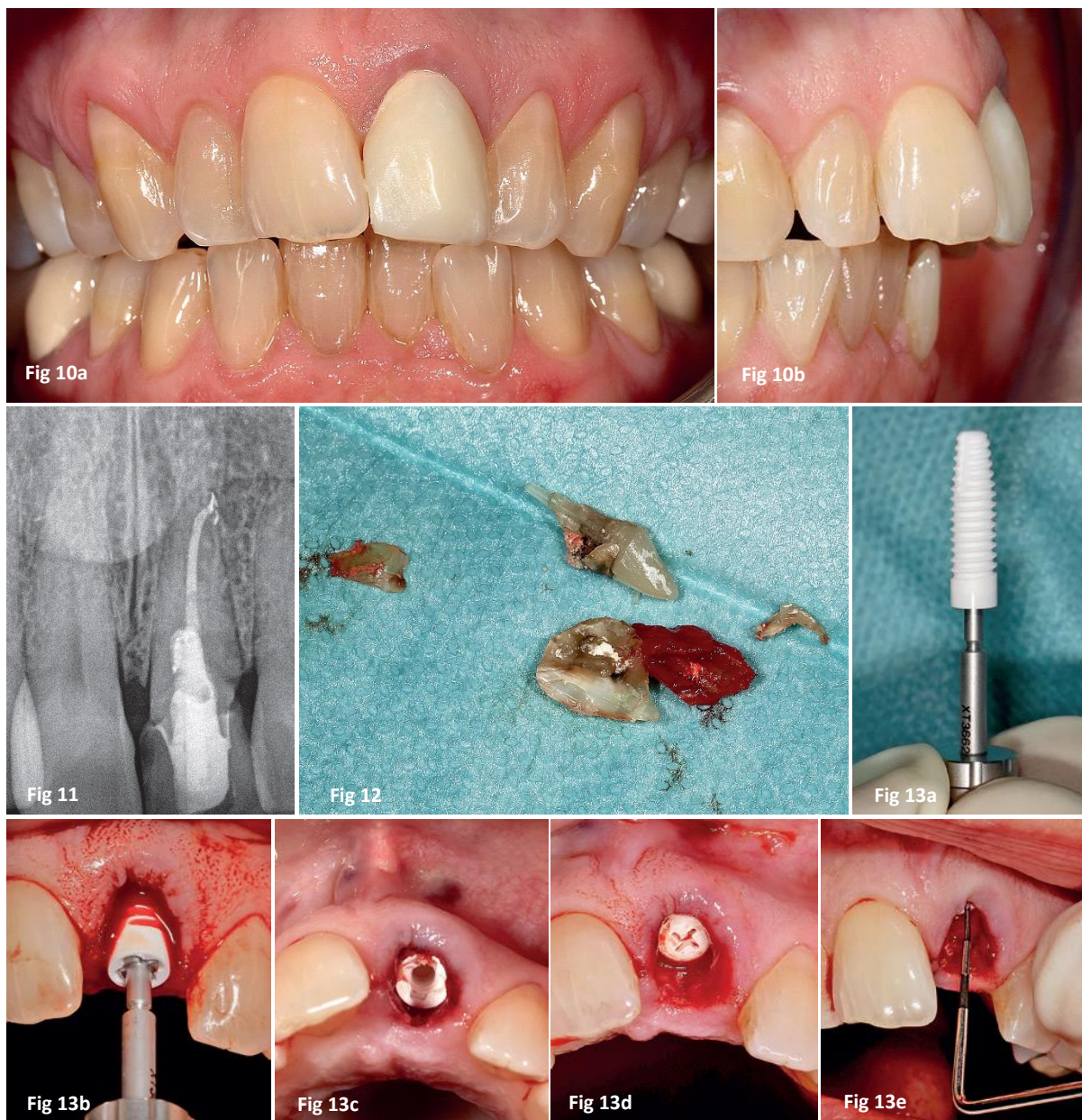
removing the VICARBO® screw, the crown was taken out of the mouth and the new emergence profile was modelled on the round abutment cross section from the subgingival edge to emulate the form of the original tooth.

After optimization by recontouring and polishing, the one-piece crown/abutment complex was screwed on the implant with the carbon fibre screw and torqued to 25 Ncm2. The occlusion on the crown/abutment complex was verified in centric and eccentric movements and contact points adjusted and the crown was further bonded to the adjacent teeth with light-cured composite. The healing period was 6 months. The impression and the fabrication of the permanent crown was done according to the manufacturer's instructions. In this case an E-max crown was bonded to the zirconia abutment and the resulting one-piece crown/abutment



**Fig 8:** Post treatment photo. **Fig 9a and 9b:** The clinical picture and X-ray inspection two years post-op show peri-implant conditions without inflammation.





**Fig 10a and b:** Clinical situation: Narrow jaw with an overjet of 9 mm. **Fig 11:** Tooth 21 had a massive palatal and sub-gingival carious lesion. **Fig 12:** Tooth 21 removed. **Fig 13 a to fig e:** After the osteotomy, the insertion of the implant was performed with high primary stability.

complex was then connected to the implant without cement using the VICARBO® screw.

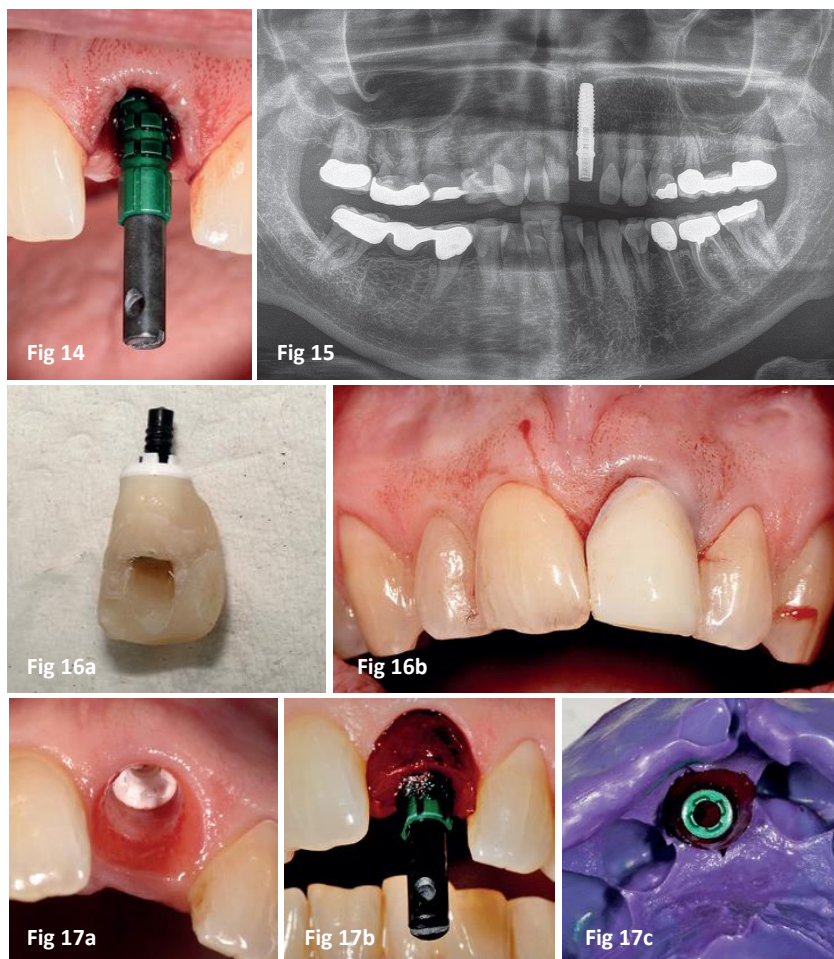
The clinical pictures after two years show absolutely no inflammation of the peri-implant tissues and the papilla height and ratio had settled to 100% of the level of the adjacent teeth. Interestingly, during this period

of observation, the buccal gingival margin migrated 1mm toward the incisal edge. No abnormal pocket formation or bleeding was observed. After two years the patient was satisfied and had no complaint. The radiograph shows almost complete osteogenesis especially considering the three-dimensional discrepancy

between the root shape and the shape of the implant body. There is a sub-gingival area of translucency on the mesial of the neck of the implant.

#### Treatment Case 2

A 45-year-old patient presented with an anterior



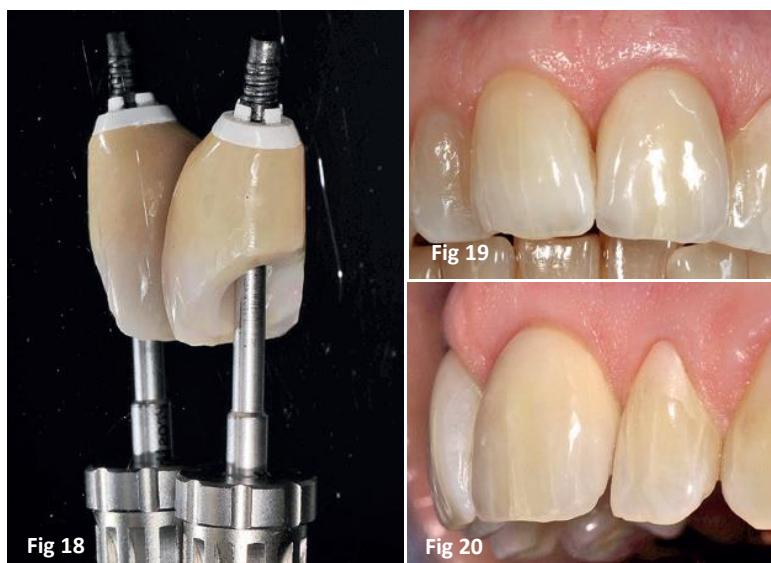
**Fig 14:** Impression post for an additional intraoperative registration in situ. **Fig 15:** OPG control image after implantation and abutment fixation. **Fig 16a & b:** Site # 21 - Temporary crown/abutment complex for six months. **Fig 17a to c:** After six months, the temporary restoration was removed. A modified open transfer sleeve was inserted for the final impression.

root-filled #21. The endodontic treatment had been performed 20 years ago. The tooth showed a massive subgingival carious lesion on the palatal aspect which compromised the stability of the tooth. A restoration was not attempted because it would have damaged the alveolar bone and compromised the bone volume in case of a subsequent implant treatment. Because of the sagittal deficit (retrognathism with anterior protrusion), a 9mm overjet and optimal bone condition, an immediate

placement was also planned in this case. The patient had a thick soft tissue phenotype and a wide alveolar ridge with thick inter-proximal septum. Thus, like case 1, there were good initial conditions for an immediate implant placement and immediate restoration. In preparation for the immediate implant placement, a silicone key was prepared before the extraction in order to fabricate a provisional crown to be used as a temporary implant crown later. In this case as well, tooth #21 was removed with a minimally

invasive technique and the buccal cortical plate was preserved from the apical to the middle two third of the alveola. After the extraction, followed the site preparation for a 4.2 diameter x 14mm length implant (ZERAMEX® XT, Dentalpoint) according to manufacturer's specifications. The alveola was identical to case 1 so the osteotomy was also positioned palatal to the incisal edge to allow later for the screw access. After threading the bone, the insertion of the implant took place with high primary stability. Due to the retrognathism there was a 6mm difference between the buccal and palatal gingival margin. The implant shoulder had to be positioned 3mm subgingivally for an optimal aesthetic emergence profile design. The provisional crown that was set aside, before the gentle extraction of tooth 21, was placed in the silicone key and repositioned on a straight zirconia abutment and adapted using a light-cured composite. Once outside the mouth, the subgingival contour was refined and adapted to the circular contour of the abutment shoulder. After further optimization with recontouring, polishing and piece crown/abutment complex was fixed to the implant with the VICARBO® screw torqued to 25 Ncm2. Additional bonding to the adjacent teeth was unnecessary because of the high primary stability and the open bite. The stress-free healing of





**Fig 18:** The final crown was made using a straight zirconia abutment.

**Fig 19:** Completion of the restoration with functional and aesthetic result.

**Fig 20:** Lateral view of the implant to visualize the emergence profile.

the implant took place over a six-month period.

After six months, the crown/abutment complex was removed in preparation for a customized silicone impression. This modified impression transfer with an identical copy of the subgingival emergence profile was then sent to the dental technician to reproduce on the final restoration. The fabrication of the permanent crown on a straight zirconia abutment was achieved according to the one-veneer system (Willi Geller). The functional and aesthetic restoration was completed to the satisfaction of the patient. The original unappealing periodontal situation had resolved, and the healthy papilla showed a similar condition to the adjacent teeth.

#### Discussion

New and innovative techniques always take time to

establish themselves. First experiences are always case studies which is then the basis for ethical planning and implementation of prospective studies. Meanwhile, despite decades of experience in titanium technology the opinions regarding immediate implant placement and immediate restoration are very diverse and sometimes even controversial – whereas in the field of ceramic implantology it is highly speculative because it is a novel technology. The two clinical cases demonstrate that an all ceramic implant system can be used for immediate implant placement with immediate restoration if the design of the implant allow for high primary stability. Years ago, a reversible screwed connection between ceramic parts would have been unthinkable. Now many manufacturers are attempting to become established in this field due to the clinical

advantages of a full ceramic technique.

However, the literature does not currently provide any comparative studies of the available connection systems. The studies currently provide the lowest level of evidence. Therefore, practitioners must use them strictly in clinical situations with optimal anatomical and functional conditions. The desire of patients for full ceramic implant solutions are often based on their skepticism of metal technology associated with the notion that ceramics have particularly good biocompatibility. This is illustrated in the cases presented in this article but also by others – such as the studies of Borgonovo et al. If we add the excellent aesthetics of ceramic implants in cases of thin soft tissue phenotype then we can conclude that there is a clear potential over titanium technology. Considering the technical maturity of currently available all-ceramic implant systems, we can predict a promising future which also justifies the initiation of prospective clinical studies.

The use of ceramic implants and superstructures requires a special understanding of zirconia as a material. This may explain previous opinions, different experiences and success rates. The completely different feel when joining zirconia parts compared to titanium technology requires a high level of precision, sensitivity and tactility – both in the surgical

and restorative phases. Therefore, ceramic implantology is a high sensitivity treatment so when planning and conducting prospective studies on ceramic implants it is necessary to be properly trained in order to avoid a distortion of the results of such studies. Full ceramic implantology in the aesthetic area has reached clinical and technical maturity so, even with the current paucity of clinical studies, a

promising future can be predicted.

## Contact

**Prof. Dr. med. Dr. med. dent. Michael Stiller**  
Private practice of Oral Surgery, Implantology and Periodontology  
11 Brahms Street  
Berlin 14193  
info@implant-consult.de  
[www.implant-consult.de](http://www.implant-consult.de)

**Dr. Barbara Peleska**  
Marburg Philipps-University,  
Centre for Dental, Oral & Maxillofacial Surgery.  
3 Georg-Voigt-Street  
Marburg 35039  
[peleska@med.uni-marburg.de](mailto:peleska@med.uni-marburg.de)

## Bibliography:

1. Van Nimwegen WG, Goené RJ, Van Daelen AC, Stellingsma K, Raghoobar GM, Meijer HJ. J Oral Rehabil. 2016 Oct;43(10):745-52. doi: 10.1111/joor.12420. Epub 2016 Aug 18. Immediate implant placement and provisionalisation in the aesthetic zone.
2. Oxby G, Oxby F, Oxby J, Saltvik T, Nilsson P. Clin Implant Dent Relat Res. 2015 Oct;17(5):898-907. doi: 10.1111/cid.12210. Epub 2014 Feb 18. Early Loading of Fluoridated Implants Placed in Fresh Extraction Sockets and Healed Bone: A 3- to 5-Year Clinical and Radiographic Follow-Up Study of 39 Consecutive Patients.
3. Del Fabbro M, Ceresoli V, Taschieri S, Ceci C, Testori T. Clin Implant Dent Relat Res 2015; 17 (1): 52-70. Immediate loading of postextraction implants in the esthetic area: systematic review of the literature
4. Lindeboom JA, Frenken JW, Dubois L, Frank M, Abbink I, Kroon FH. J Oral Maxillofac Surg. 2006 Jun;64(6):936-42. Immediate loading versus immediate provisionalization of maxillary single-tooth replacements: a prospective randomized study with BioComp implants.
5. Stiller M, Peleska B, Hmaidouch R, Mehrhof J, Weigel D. Dentofacial composition: An entire aesthetic concept. Facial Plastic Surgery 2015; 31 (4): 504-512
6. Sivaraman K, Chopra A, Narayan AI, Balakrishnan D. J Prosthodont Res. 2018 Apr;62(2):121-133. doi: 10.1016/j.jpor.2017.07.003. Epub 2017 Aug 18. Is zirconia a viable alternative to titanium for oral implant? A critical review.
7. Borgonovo AE, Corrocher G, Dolci M, Censi R, Vavassori V, Maiorana C. Eur J Esthet Dent. 2013 Winter;8(4):532-45. Clinical evaluation of zirconium dental implants placed in esthetic areas: a case series study.
8. Borgonovo, AE, Censi R, Vavssori V, Arnaboli O, Maiorana C, Re D Zirconia implants in esthetic areas: 4-year follow up study Int J Dent 2015: published online 2015 Jun 1.
9. Kniha K, Schlegel KA, Kniha H, Modabber A, Hölzle F, Kniha K. Int J Oral Maxillofac Surg. 2018 Apr;47(4):492-498. doi: 10.1016/j.ijom.2017.10.013. Epub 2017 Nov 7. Evaluation of peri-implant bone levels and soft tissue dimensions around zirconia implants-a three-year follow-up study.
10. Kniha K, Modabber A, Kniha H, Möhlhenrich SC, Hölzle F, Milz S. Br J Oral Maxillofac Surg. 2018 Jan;56(1):43-47. doi: 10.1016/j.bjoms.2017.11.005. Epub 2017 Nov 24. Dimensions of hard and soft tissue around adjacent, compared with single-tooth, zirconia implants.